

ASU 3

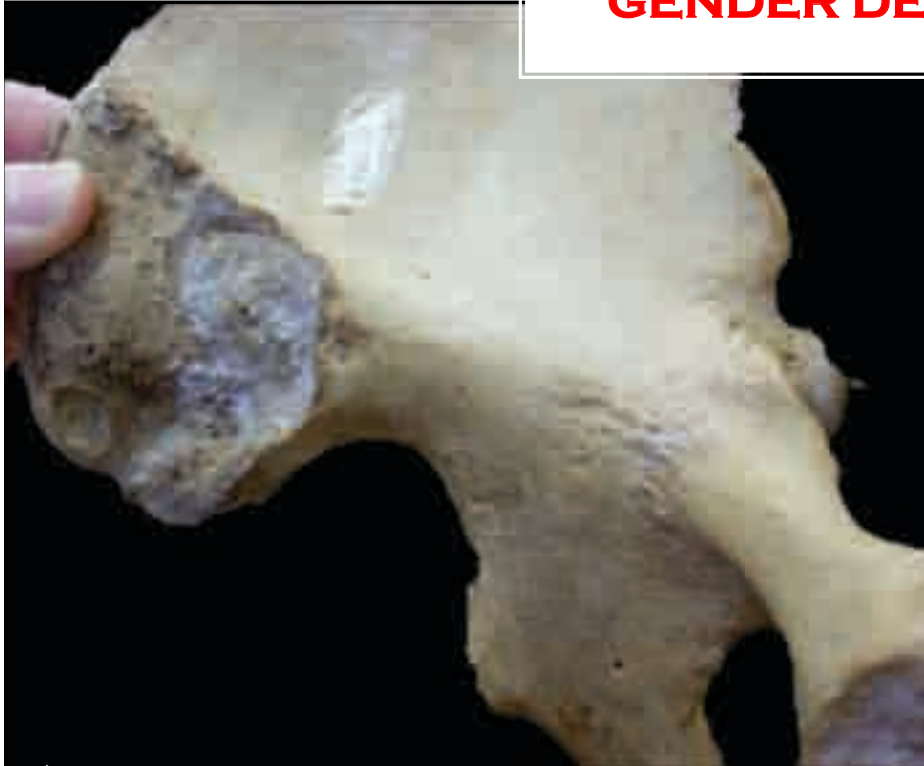A black and white photograph of a city skyline, likely New York City, viewed from an elevated train track. The tracks run diagonally from the bottom right towards the center. In the background, several skyscrapers are visible under a cloudy sky. The text 'ASU 3' is overlaid in red in the upper right corner.

JULIA HOUSER

MAYA CRAIG-LAUER

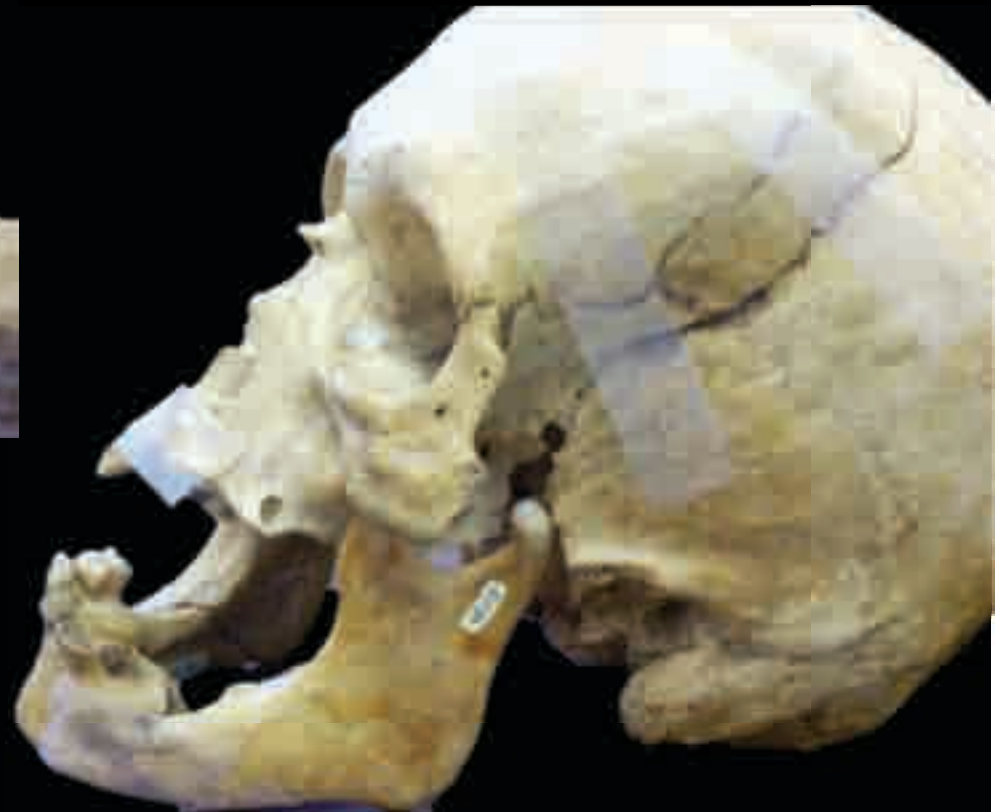GEORGIA PEARCE

GENDER DETERMINATION



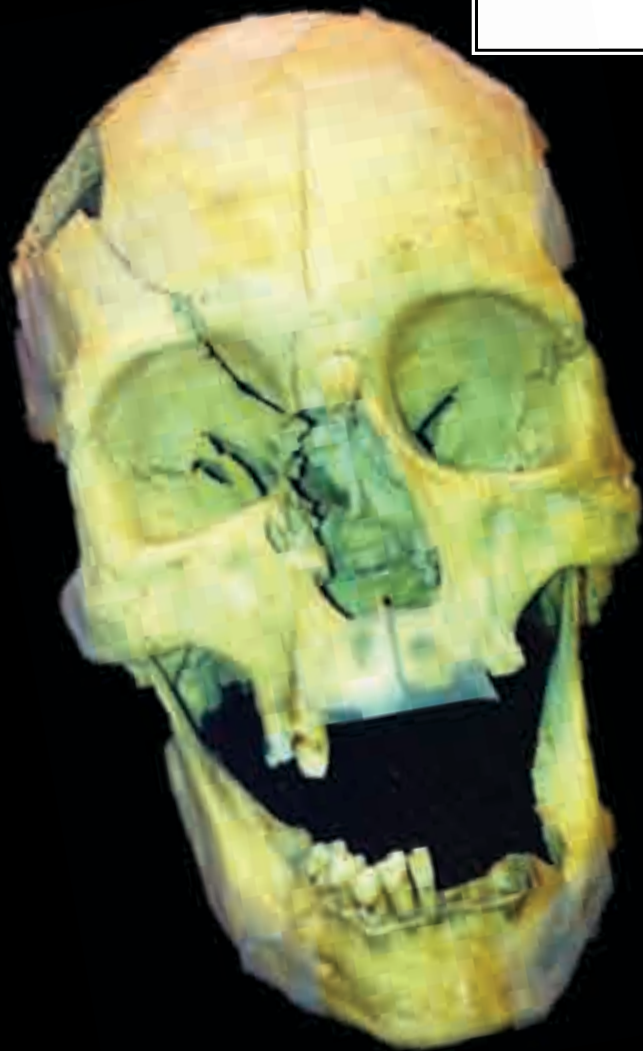
- ❖ Narrow sciatic notch
- ❖ Narrow subpubic angle

- ❖ Large mastoid processes
- ❖ Flared mandible



CONCLUSION: MALE

ANCESTRY

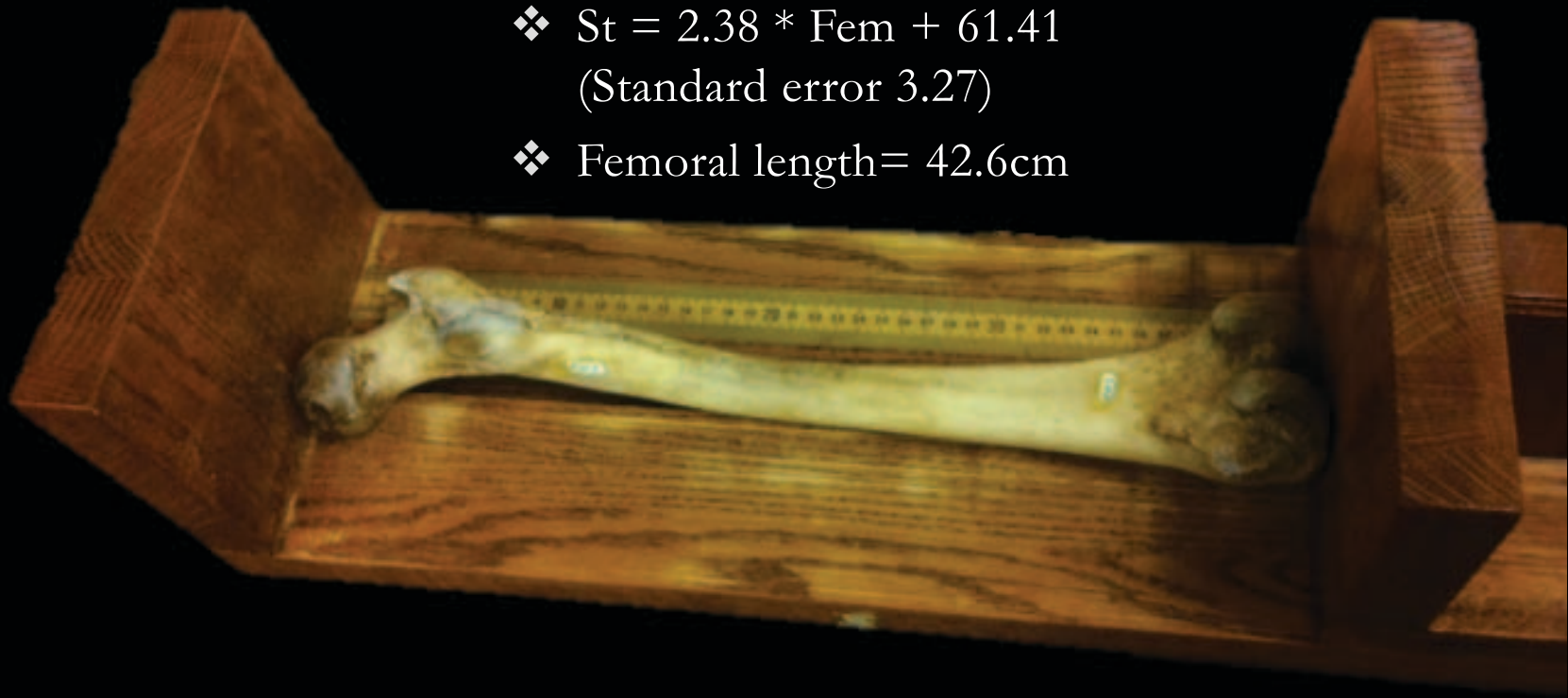


- ❖ High, narrow nasal root
- ❖ Angular eye orbits
- ❖ Receding lower eye border
- ❖ Heavy browridges
- ❖ Straight postbregma
- ❖ Small jaws

CONCLUSION: WHITE

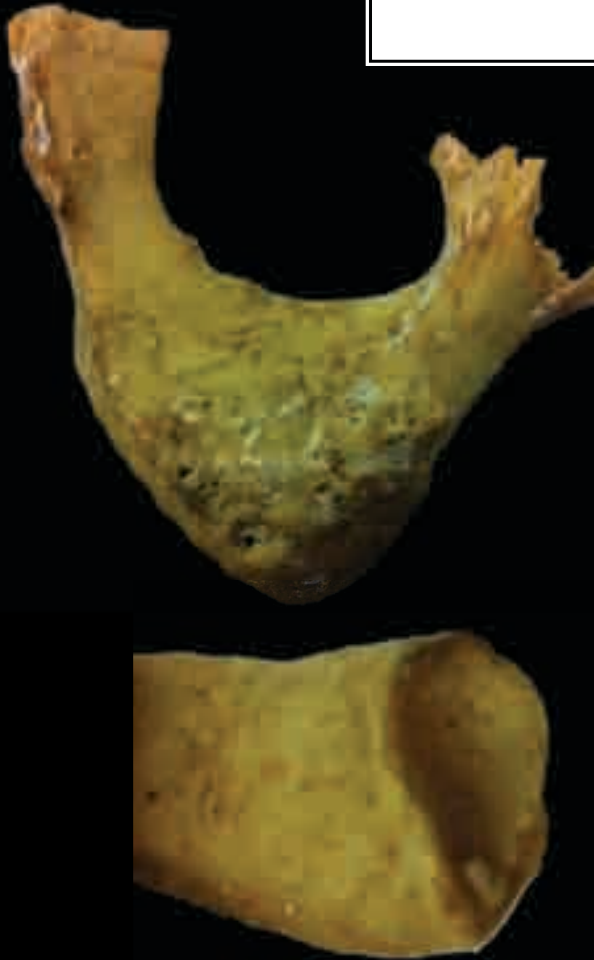STATURE

- ❖ $St = 2.38 * Fem + 61.41$
(Standard error 3.27)
- ❖ Femoral length = 42.6cm



CONCLUSION: $\approx 162.8\text{cm}$ (5' 5'')

AGE



- ❖ Pubic symphysis indicates an age range of 21-46
- ❖ Sternal rib endings designate an age range 43-55

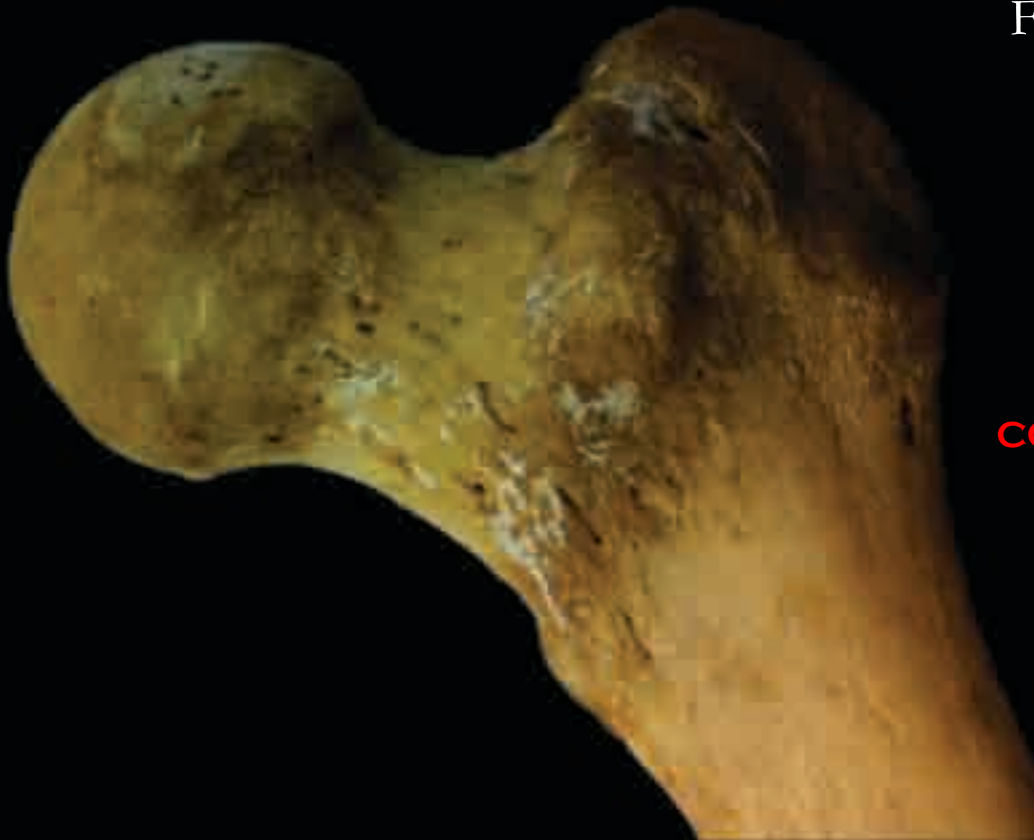CONCLUSION: MID-FORTIES (43-46)

BODY MASS

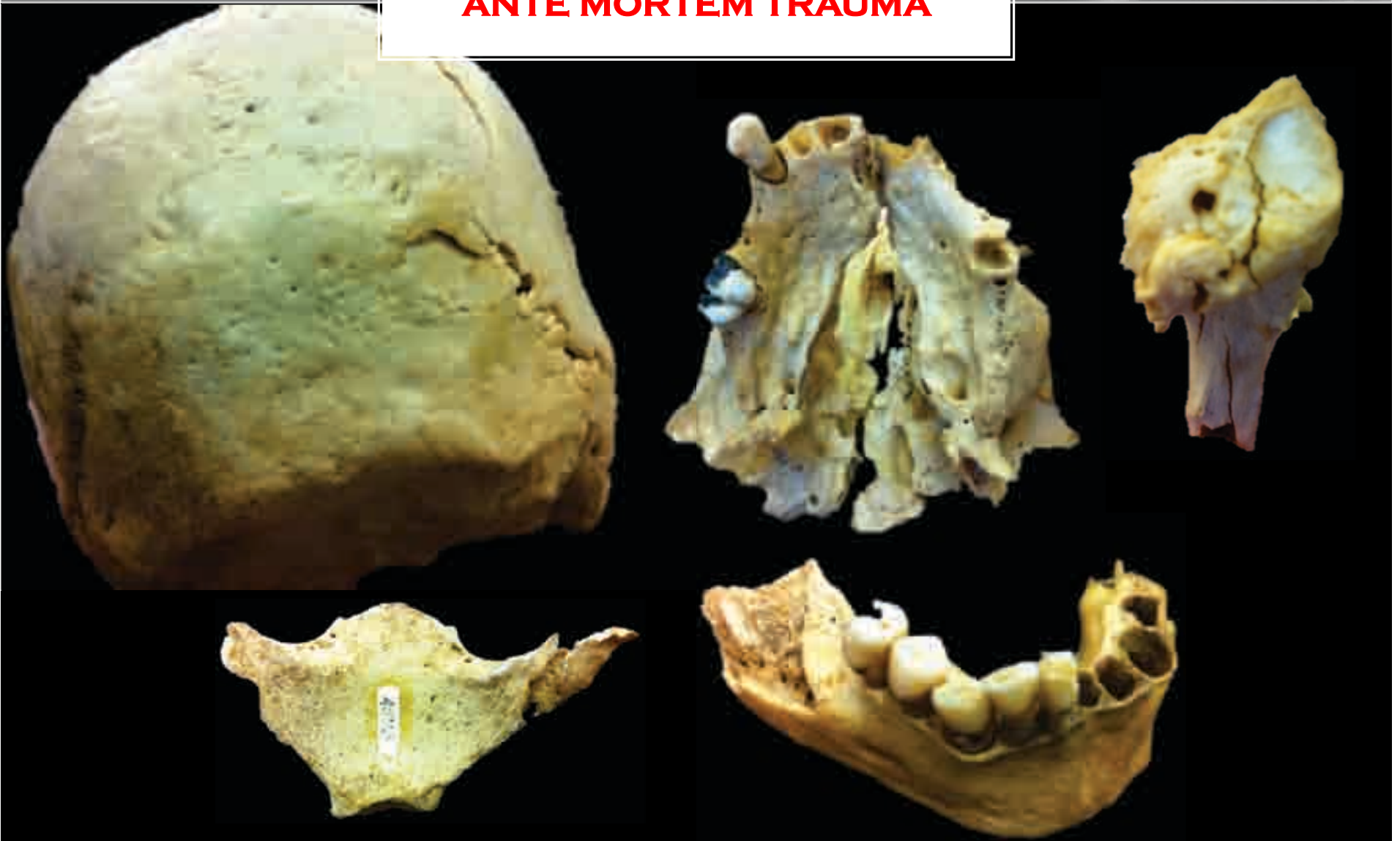$$BM = (2.741 \times FH - 54.9) \times .90$$

$$FH = 41 \text{ cm}$$

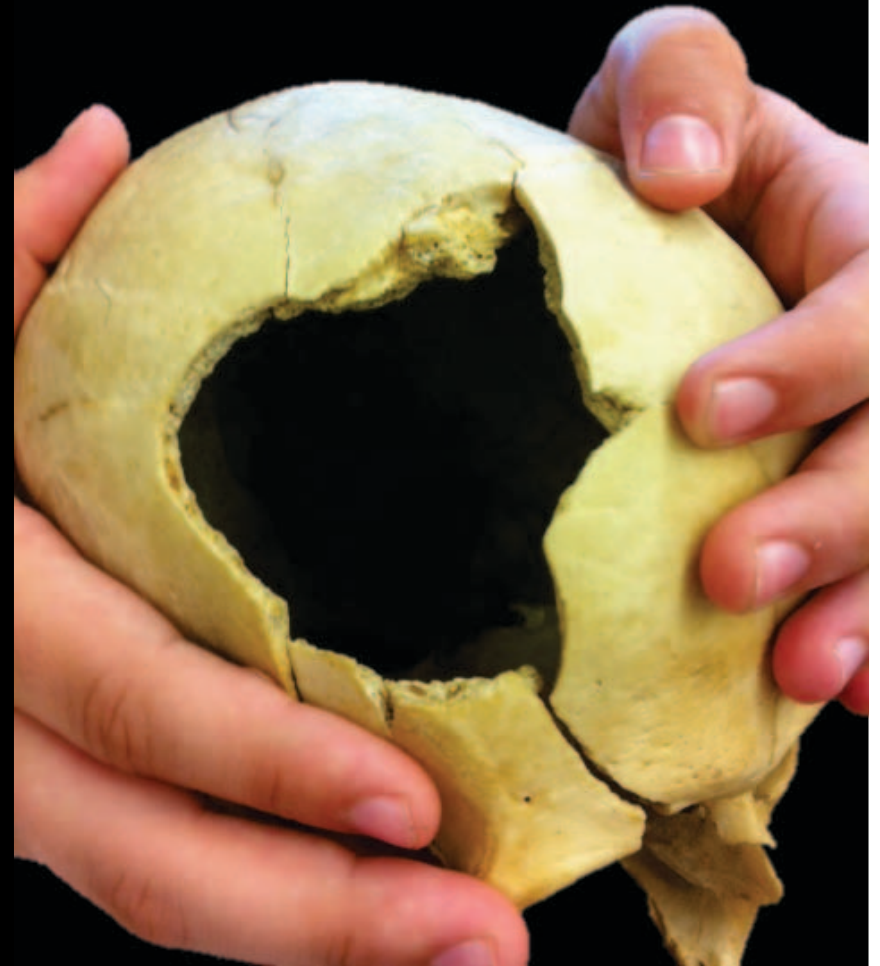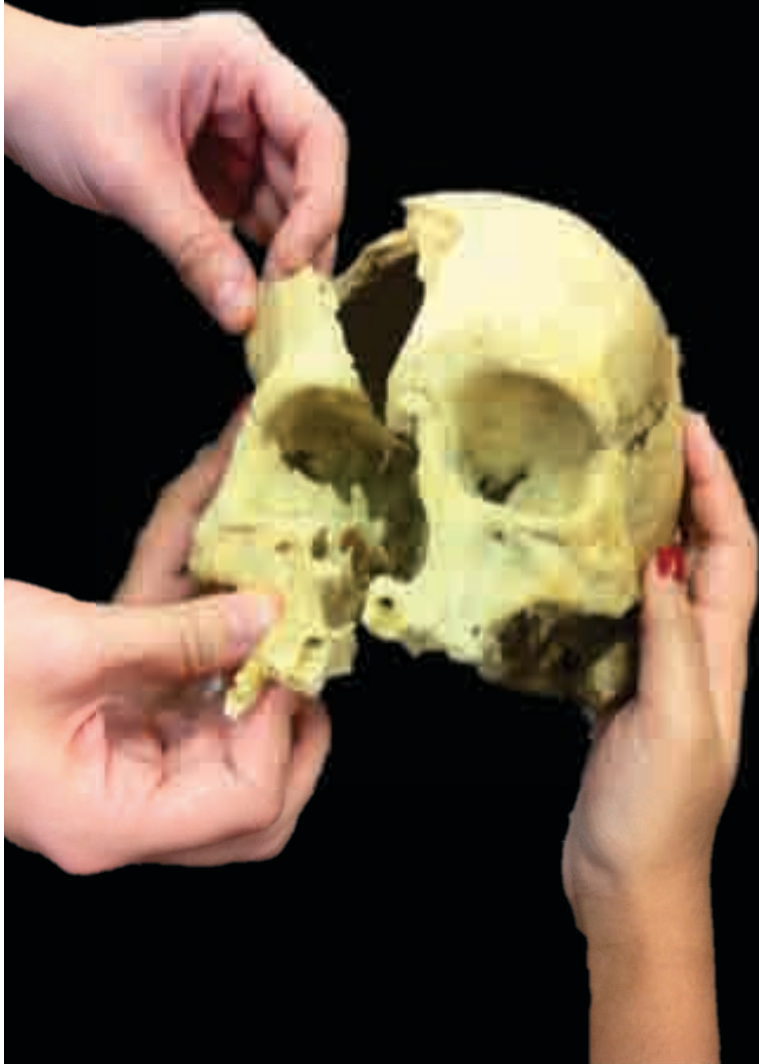CONCLUSION: BM = 51.73 KG (130.37 LBS)



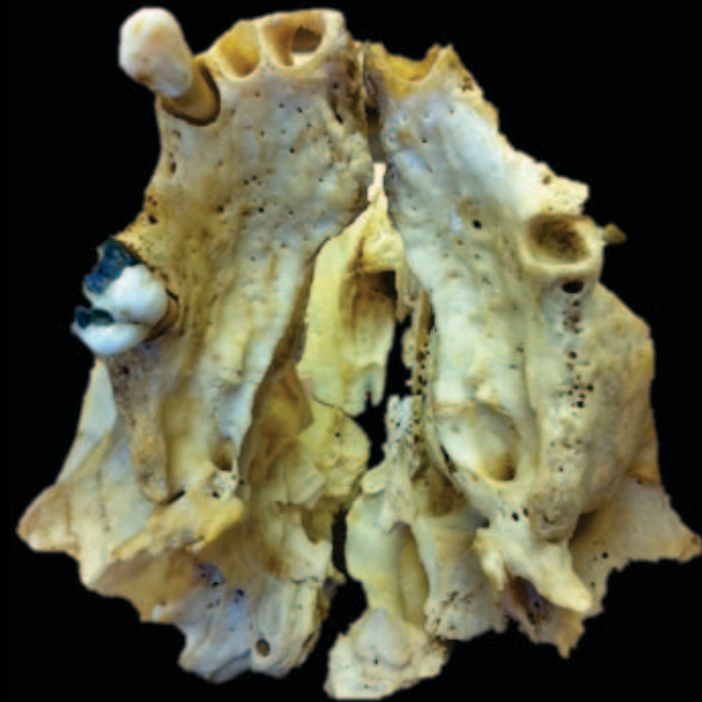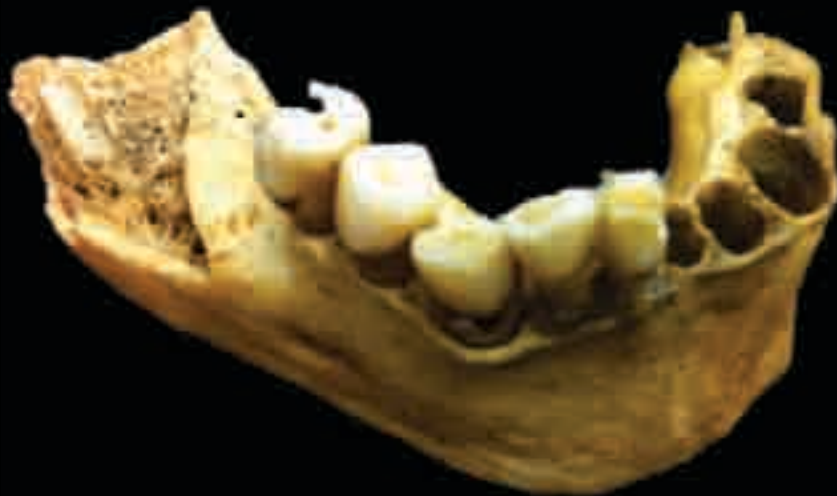ANTE MORTEM TRAUMA



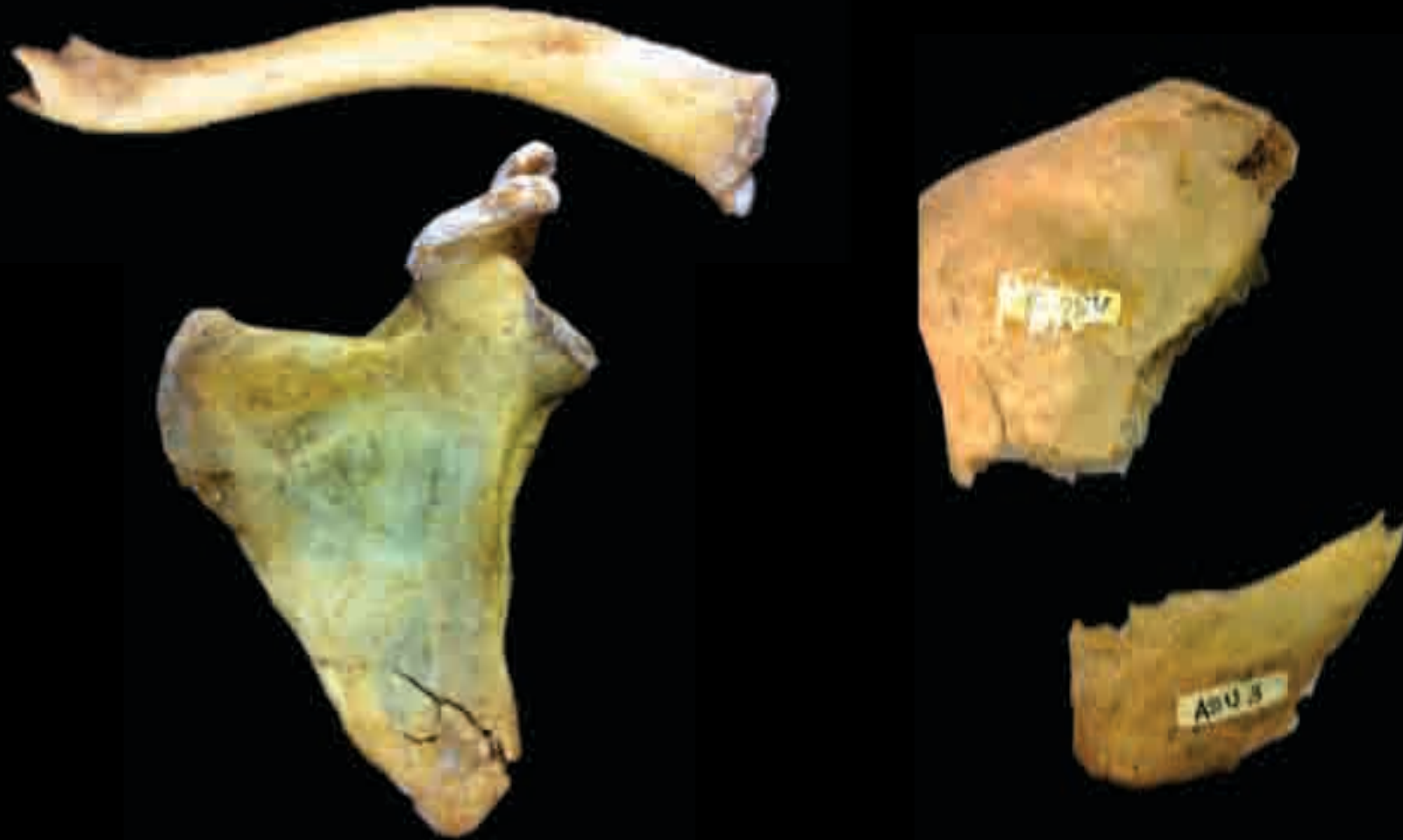TRAUMA
SKULL



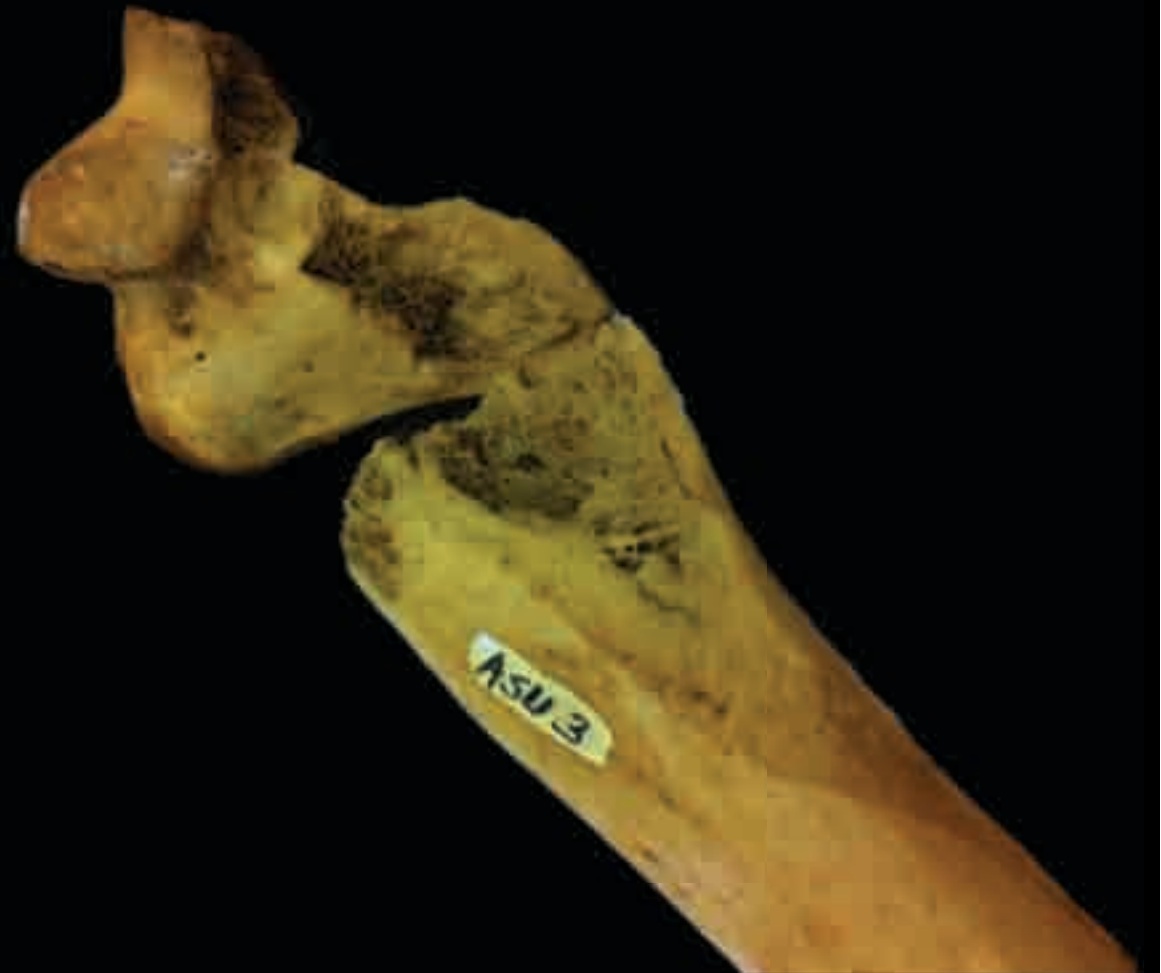TRAUMA
SKULL



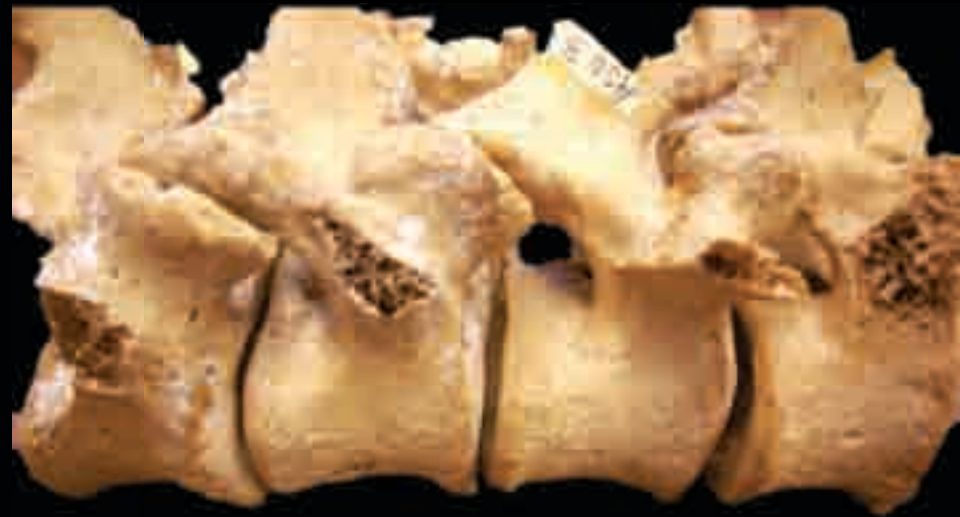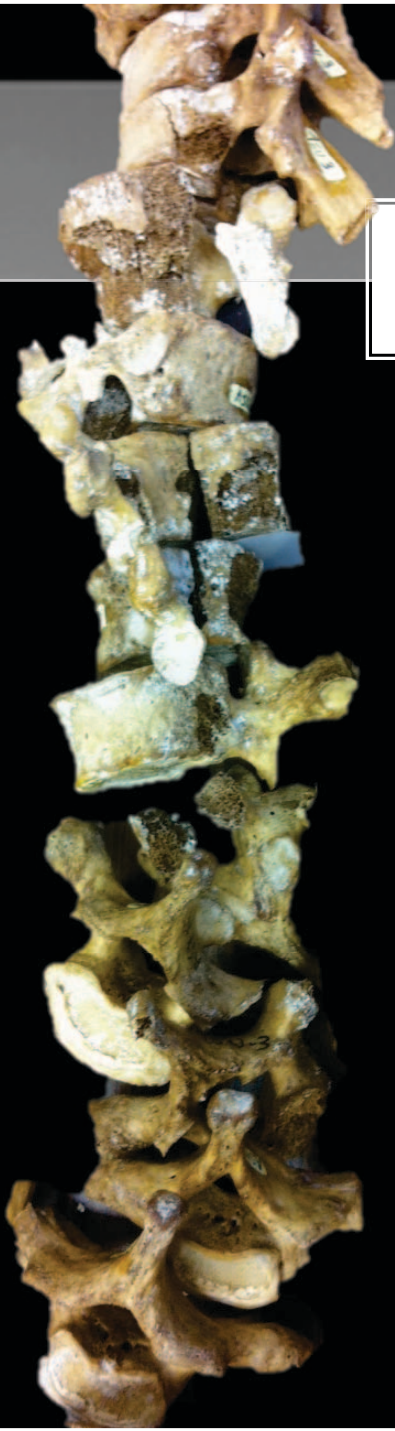
TRAUMA
CLAVICLE & SCAPULAE




**TRAUMA
HUMERUS**



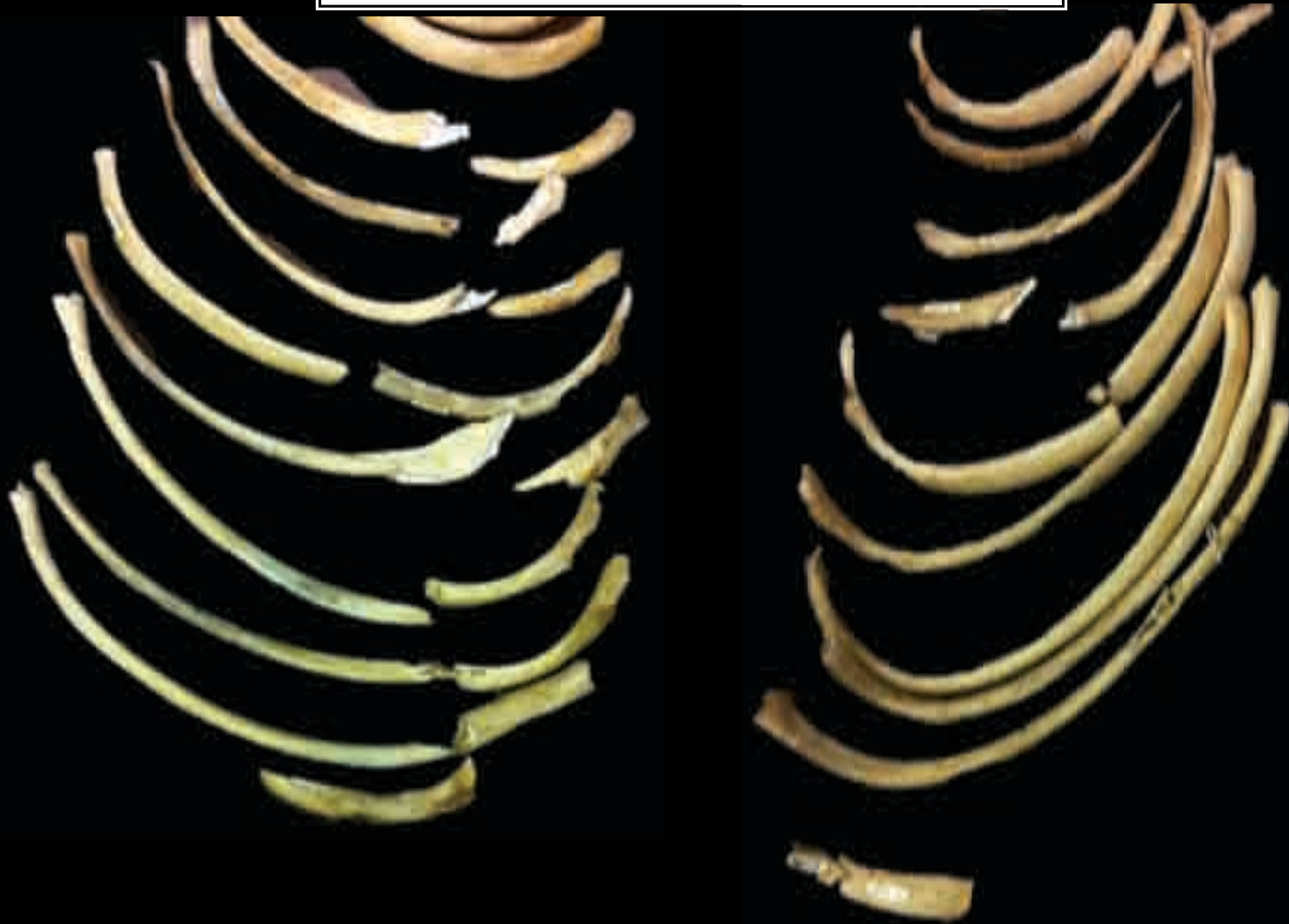
**TRAUMA
VERTEBRAE**



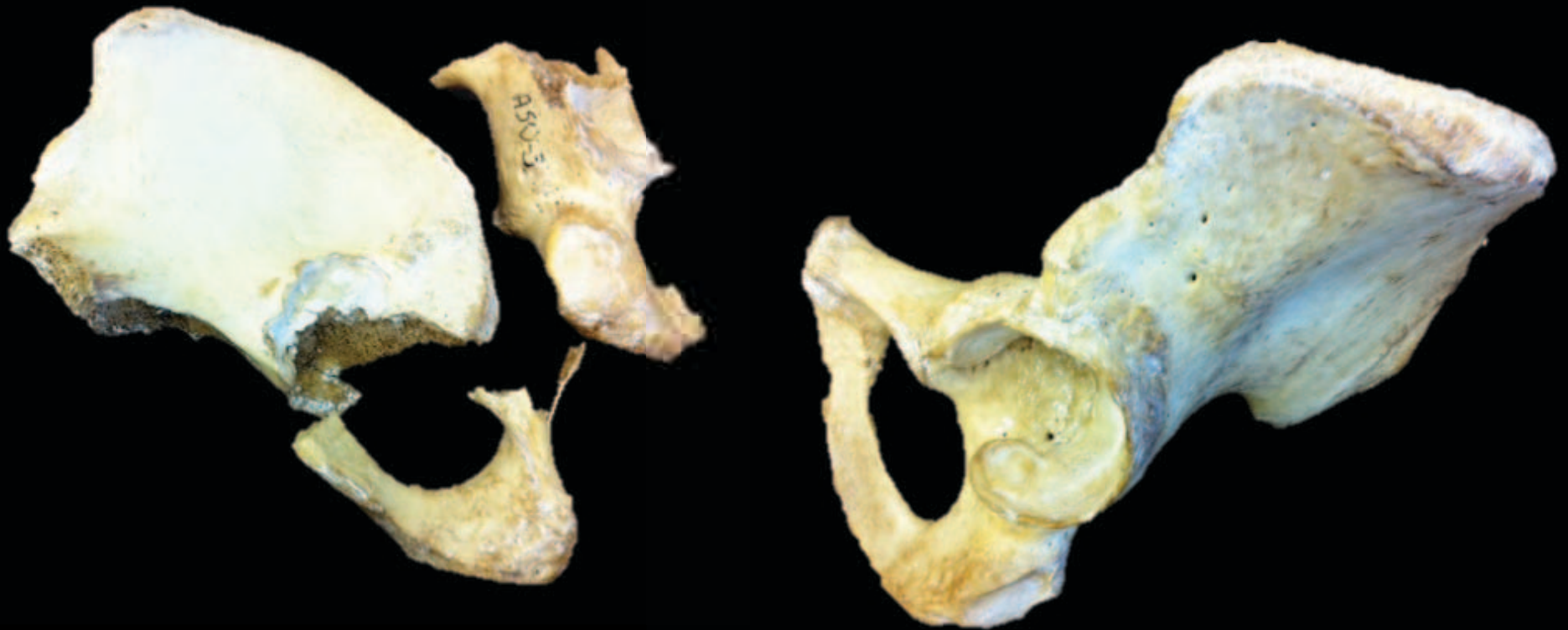
TRAUMA
SACRUM & STERNUM



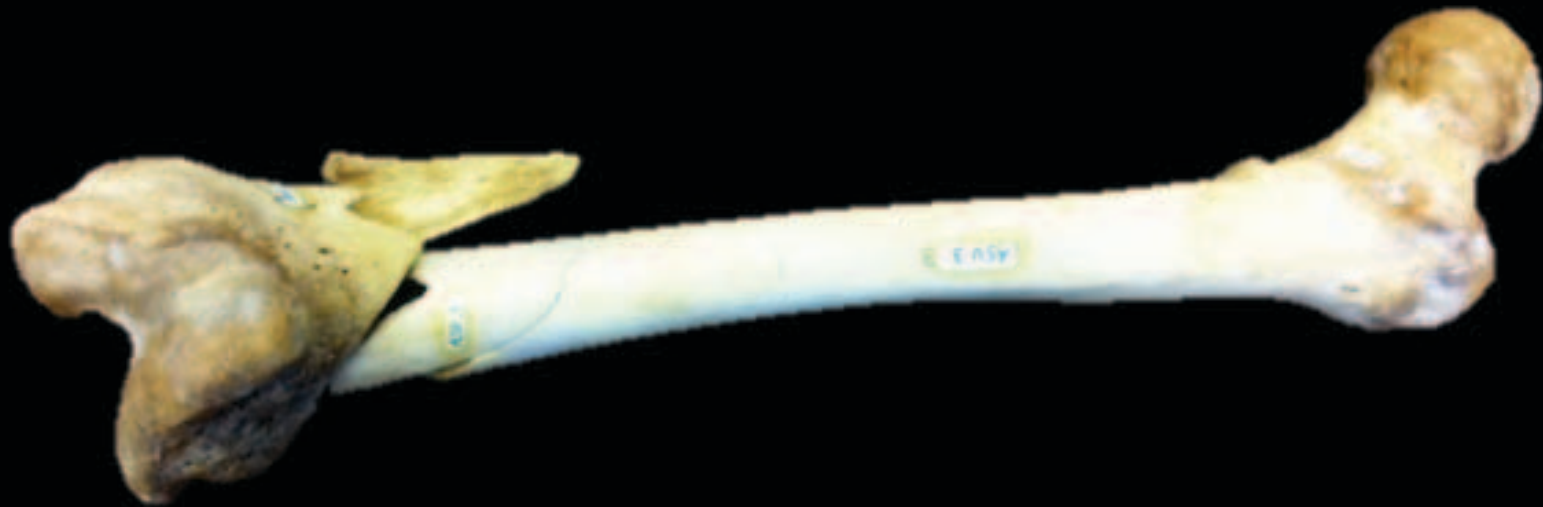TRAUMA
RIBS



TRAUMA
OX COXAE



TRAUMA
FEMURS



TRAUMA
TIBIAS & FIBULAS



