

A large pile of human bones, including a skull, used as a background for a slide about the appendicular skeleton.

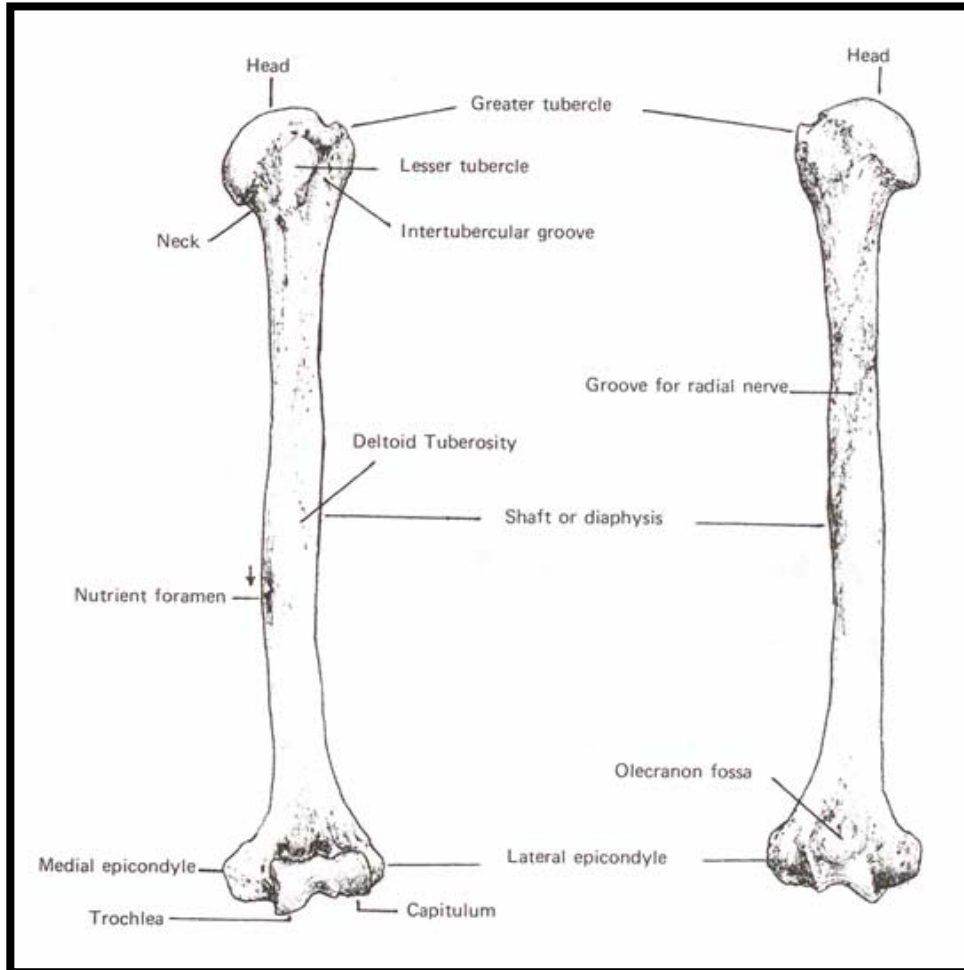
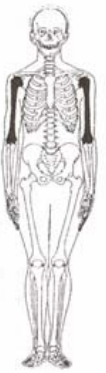# Appendicular Skeleton

Proximal Elements

# Outline: Long Bones

- Arm (brachium):
  - Humerus
- Forearm (antebrachium):
  - Ulna
  - Radius
- Thigh
  - Femur
- Leg (crus):
  - Tibia
  - Fibula

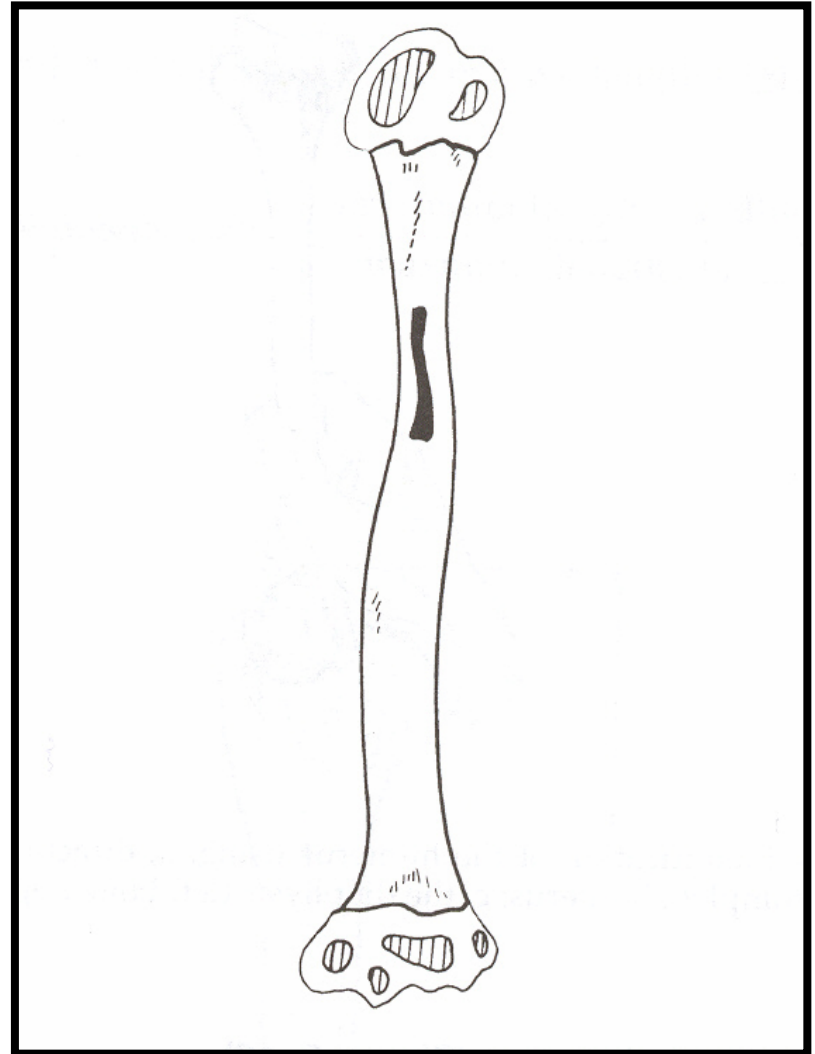
# Humerus (i) paired



- Proximal
  - Head
  - Neck
  - Greater tubercle/tuberosity
  - Lesser tubercle/tuberosity
  - Intertubercular groove (sulcus)/bicipital groove
- Shaft
  - Shaft
  - Deltoid tuberosity
  - Nutient foramen
- Distal
  - Coronoid fossa
  - Radial fossa
  - Olecranon fossa
  - Lateral epicondyle
  - Medial epicondyle
  - Trochlea
  - Capitulum

# Humeral Growth

- 8 centers
- Shaft, primary 8<sup>th</sup> week
- Proximal end:
  - Head 6 mo after birth,
  - Both tubercles in years 1-5
  - Fuse ~6, single proximal center
  - Proximal end unites with shaft in early adulthood
- Distal end:
  - Capitulum in 1<sup>st</sup> year
  - Medial Trochlea ~9-10<sup>th</sup> years
  - Lateral Epicondyle ~12<sup>th</sup> year
  - These 3 fuse join in puberty
  - Distal end unites with shaft ~14-16
  - Medial Epicondyle 4-6<sup>th</sup> years, fuses ~20



# Identification of the Humerus

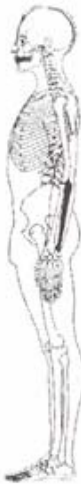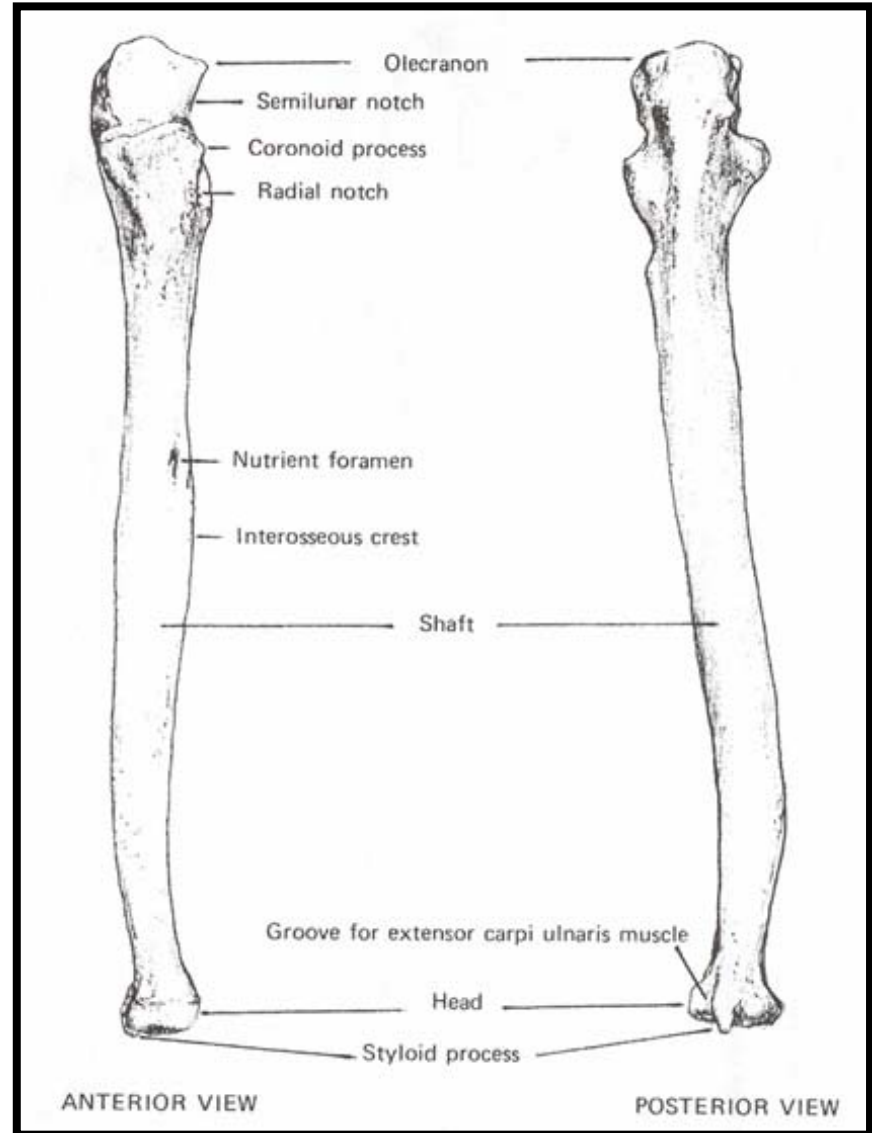
- Humerus can be confused with the femur, but the head of the humerus is small and not nearly as spherical. The humeral head does not have a fovea like the femoral head.
- Humeral shaft is larger and rounder than radial, ulnar or fibular, smaller than femoral and lacks linea aspera, smaller than tibial and not triangular.

# Siding the Humerus

- Proximal: head is medial and tubercles are anterior
- Shaft: deltoid tuberosity is lateral and nutrient foramen exits towards proximal end
- Distal: olecranon fossa is posterior, capitulum is lateral and trochlea is medial, also medial epicondyle is larger.

# Ulna (e) paired

- Proximal
  - Olecranon process
  - Trochlear notch/Semilunar notch
  - Coronoid process
  - Radial notch
- Shaft
  - Shaft
  - Ulnar (brachial) tuberosity
  - Nutrient foramen
  - Interosseous crest
- Distal
  - Head
  - Styloid process
  - Styloid groove



# Ulnar Growth

- Shaft, 8<sup>th</sup> Week
- Distal end, ~5-6<sup>th</sup> year
  - Unites to shaft ~17-18<sup>th</sup>
- Proximal end (actually 2-3 centers) appears early puberty
  - Unites ~14<sup>th</sup>-16<sup>th</sup> year

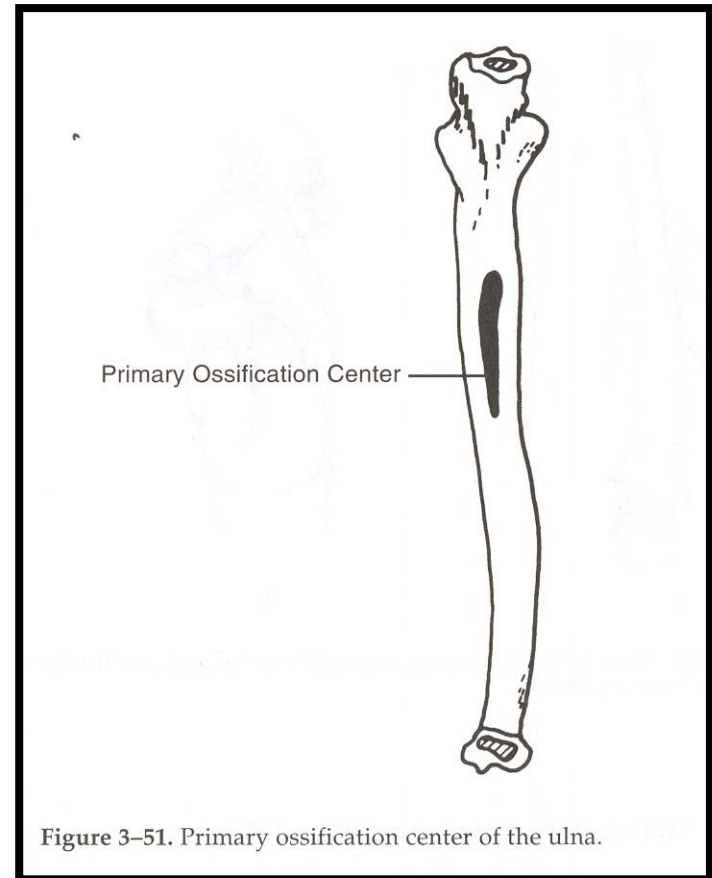


Figure 3-51. Primary ossification center of the ulna.

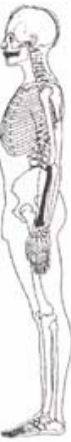# Identification of the Ulna

- Unusual hook articulation makes identification of the complete bone easy
- Proximal fragments can be confused with acetabular fragments, but look for radial facet
- When fragmentary the ulna can be mistaken for the radius or the fibula (particularly shaft fragments). However, the radius doesn't taper distally and the fibula has many flat surfaces with sharp edges

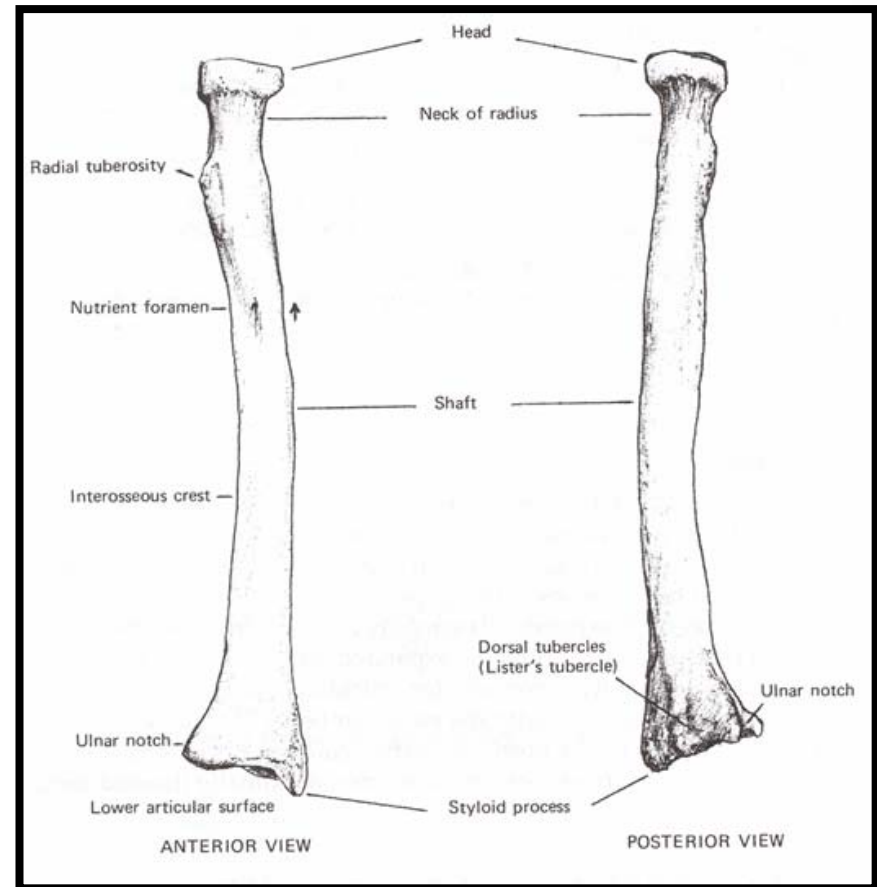
# Siding the Ulna

- For the entire ulna or the proximal end, the olecranon process is proximal and the radial notch and interosseous crest are lateral
- For isolated shaft fragments, the shaft tapers distally, the nutrient foramen exits the bone distally and is located on the anterior surface, and the interosseous crest is directed laterally
- For isolated distal ends, the styloid process is posterior and the groove is lateral to the process

# Radius (i) paired

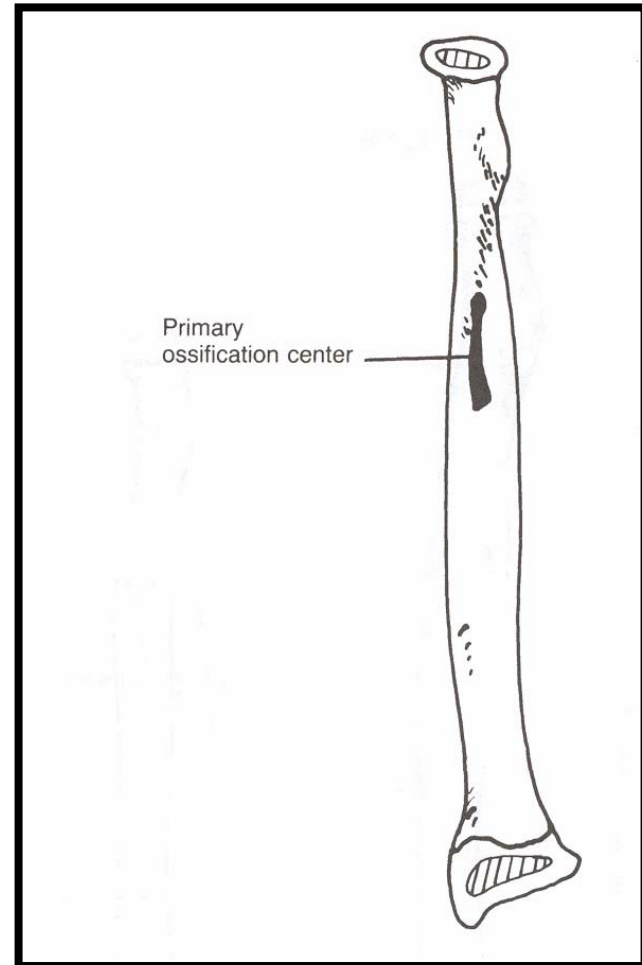


- Proximal
  - Head
  - Fovea of capitulum
  - Neck
  - Radial (bicipital tuberosity)
- Shaft
  - Shaft
  - Nutrient foramen
  - Interosseous crest
- Distal
  - Styloid process
  - Ulnar notch
  - Dorsal tubercle



# Radial Growth

- Shaft appears 8<sup>th</sup> week
- Distal epiphysis appears in 1<sup>st</sup> year
  - Unites with shaft ~17<sup>th</sup> - 19<sup>th</sup> years
- Proximal ~4-5<sup>th</sup> year
  - Unites with shaft ~14-17<sup>th</sup> year
- A fourth center on tuberosity variably present in late puberty



# Identification of the Radius

- Shaft can be confused with ulnar and fibular shafts, but radius is “teardrop-shaped” in cross-section, ulna is tapered and more triangular in cross-section, fibula is more irregular.
- Distal end has two clear surfaces for articulation.

# Siding of the Radius

- Proximal: tuberosity is medial and anterior, medial side of the head extends more proximally than lateral
- Shaft: interosseus crest is medial, oblique line is anterior, nutrient foramen exits distally and is anterior
- Distal: anterior surface is smooth, posterior grooved, ulnar notch is medial, styloid process is lateral