

A close-up photograph of a pair of adult hands gently cupping a baby's feet. The hands are positioned on either side of the feet, with the fingers slightly curled. The baby's feet are the central focus, showing the toes and the arch of the foot. The background is a dark, textured surface, possibly a piece of fabric.

Appendicular Skeleton 3:

Hands and Feet

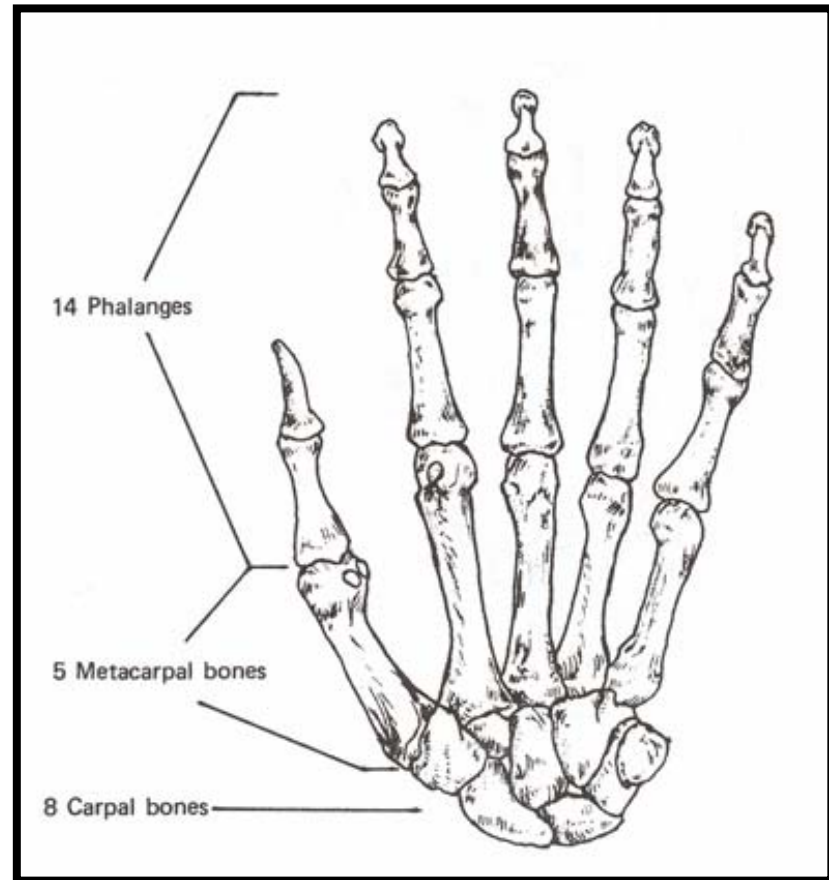
Outline

- Hand (Manus)
 - Wrist (carpus)
 - Hand (metacarpus)
 - Fingers (digits)
- Pes (Foot)
 - Ankle (tarsus)
 - Foot (metatarsus)
 - Toes (digits)

Carpals (Lateral to Medial)



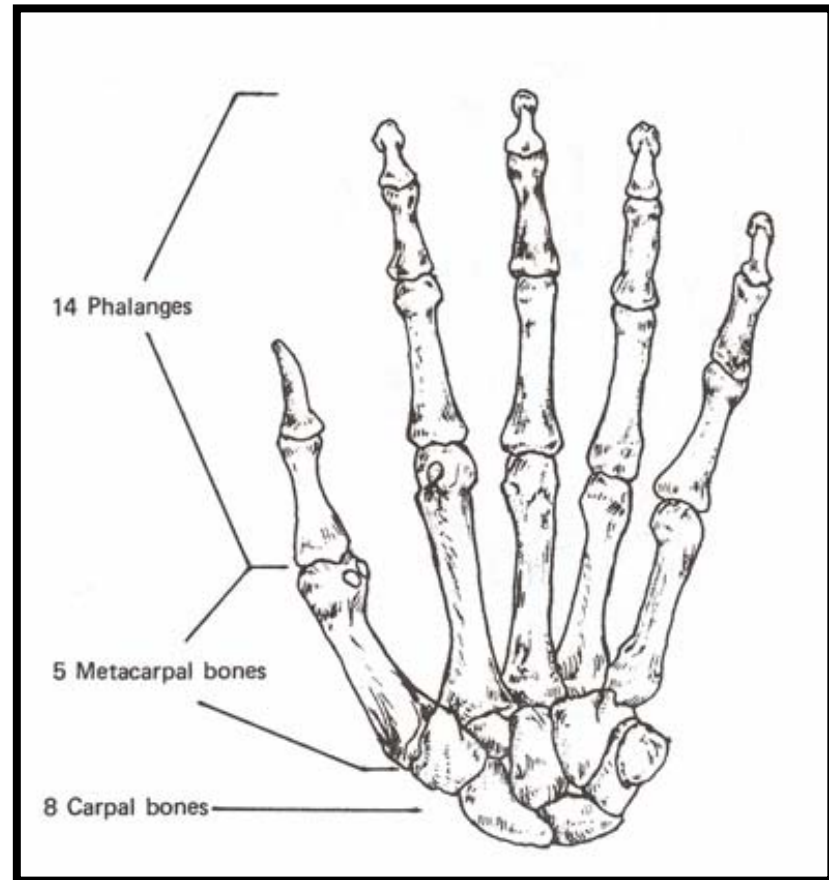
- Row 1
 - Scaphoid (=Navicular)
 - Lunate
 - Triquetral
 - Pisiform
- Row 2
 - Trapezium (=Greater Multangular)
 - Trapezoid (=Lesser Multangular)
 - Capitate
 - Hamate



Metacarpals (5)

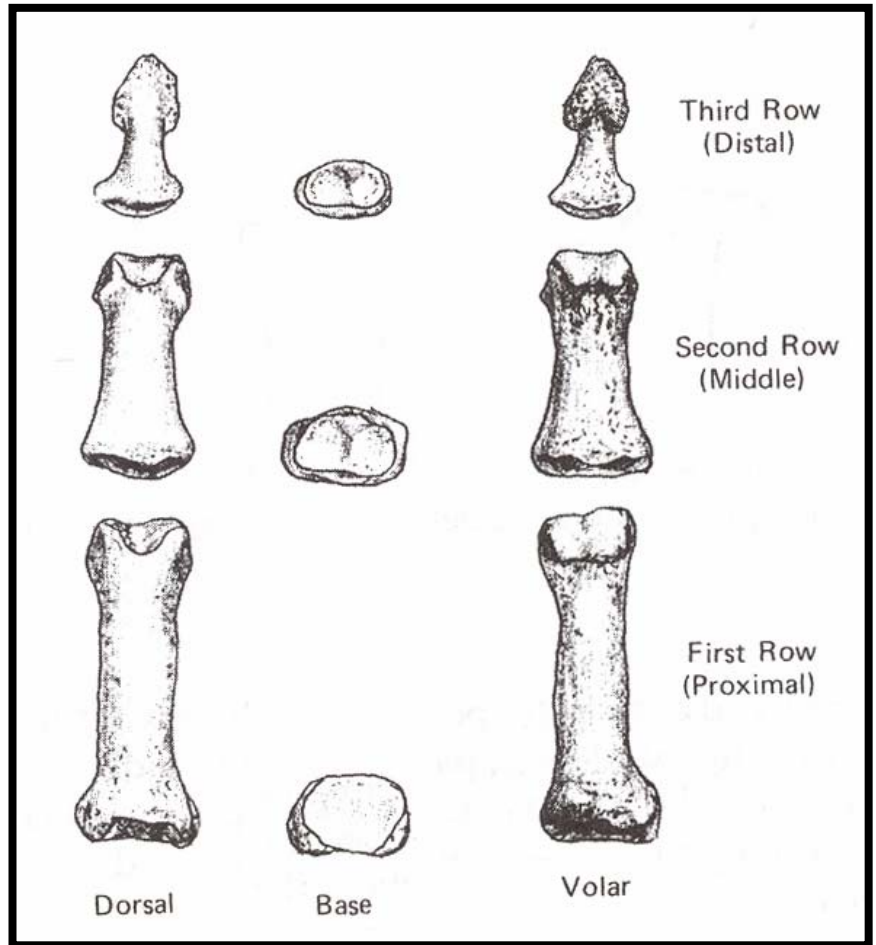


- Numbered from lateral to medial
- First is shorter and more robust
- Saddle shaped proximal end and ball-shaped distal end
- Proximal end of first is true sellar joint
- Palmar side is convex



Phalanges (14)

- Three rows (phalanxes):
 - 1st (proximal, basal)
 - 2nd (medial, intermediate)
 - 3rd (distal, ungual)
- Thumb (=pollex) lacks intermediate phalanx



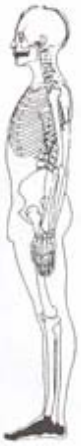Hand Bone Growth

- Carpal Bones:
 - Single Ossification Center
 - Capitate first (2nd postnatal month), pisiform last (~9th – 12th year)
- Metacarpal Bones II-V:
 - Proximal and Shaft: 9th week, from medial to lateral
 - Distal End: 2nd year
 - Unite between 15-19th year
 - MC I is like a phalanx, shaft: 9th week, proximal end 2-3rd year, uniting ~15-17th year
- Phalanges:
 - Proximal End: ~8-11th week
 - Shaft and Distal: 2-4th year
 - Unite 14-18th year

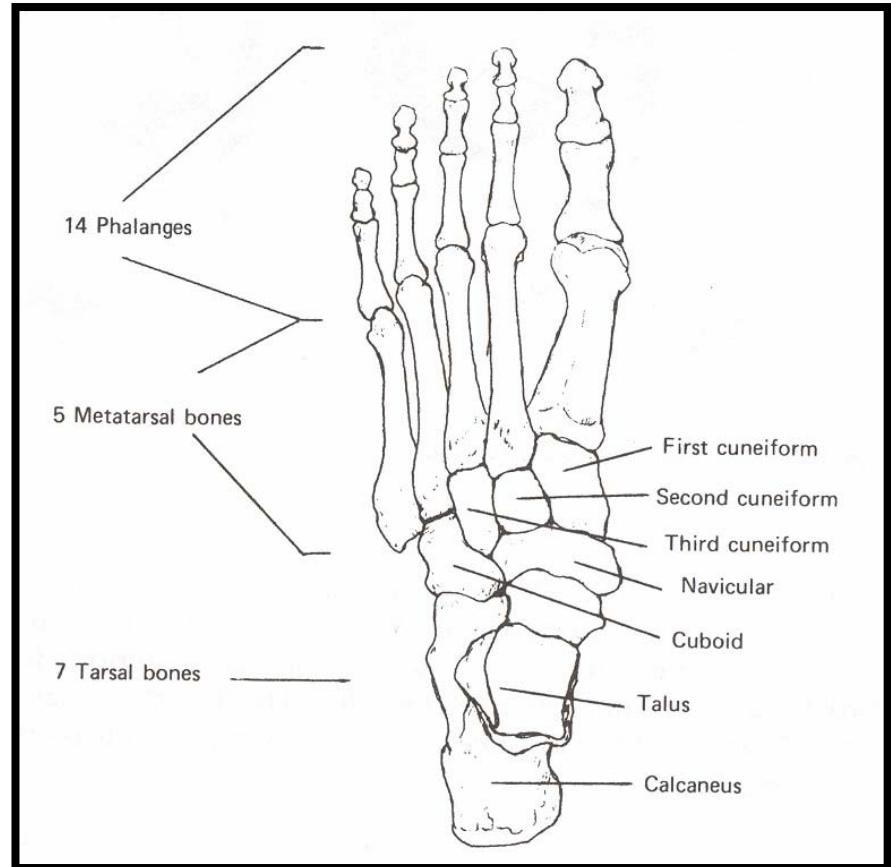
Identification

- Proximal: simple, concave proximal facet; double convex distal facet
- Medial: double concave proximal facet; double convex distal facet
- Distal: double concave proximal facet; flattened distally
- Pollical phalanges are shorter and broader

Tarsals (7)

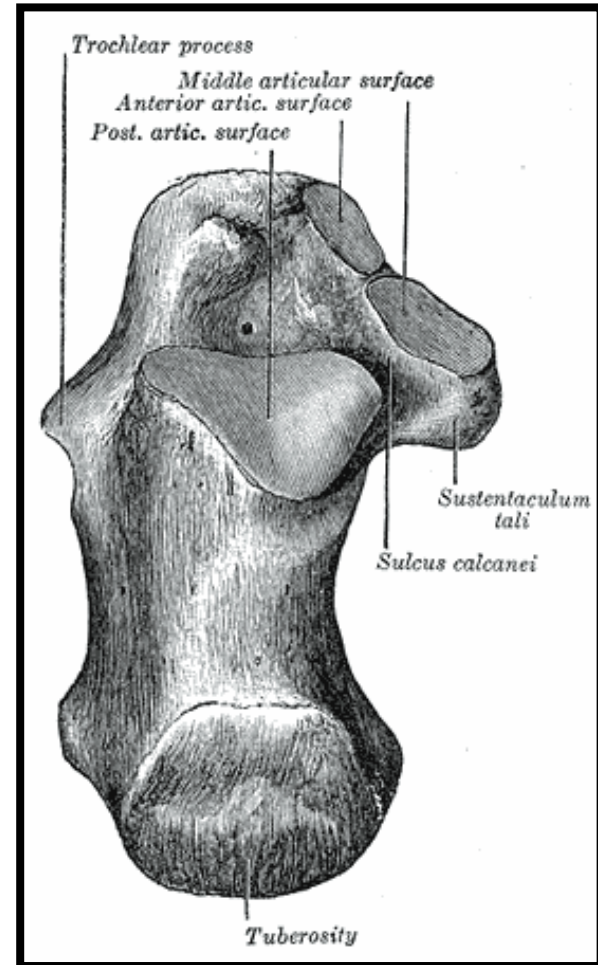


- Tarsus longer than Carpus
- Group 1
 - Talus (=Astragalus)
 - Calcaneus
 - Navicular
- Group 2 (lateral to medial)
 - Cuboid
 - Lateral Cuneiform (3rd)
 - Intermediate Cuneiform (2nd)
 - Medial Cuneiform



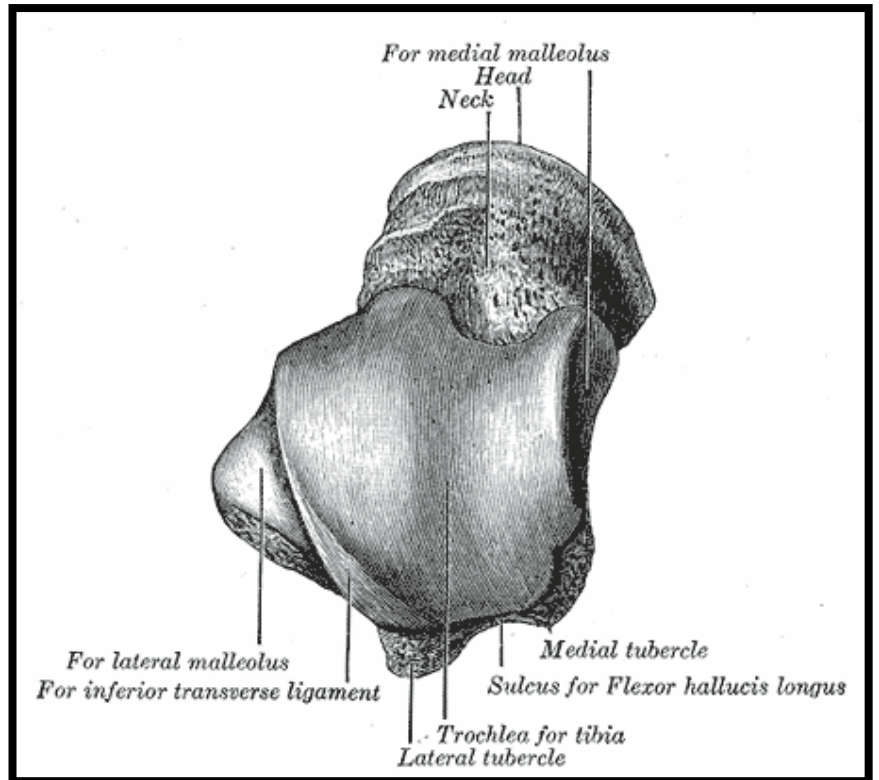
Calcaneus

- Tuberosity
- Sustentaculum tali
- Talar Articular facets
- Siding: sustentaculum is medial, tuberosity posterior, talar facets superior

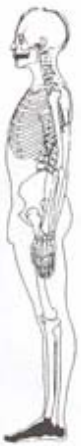

Talus (=Astragalus)

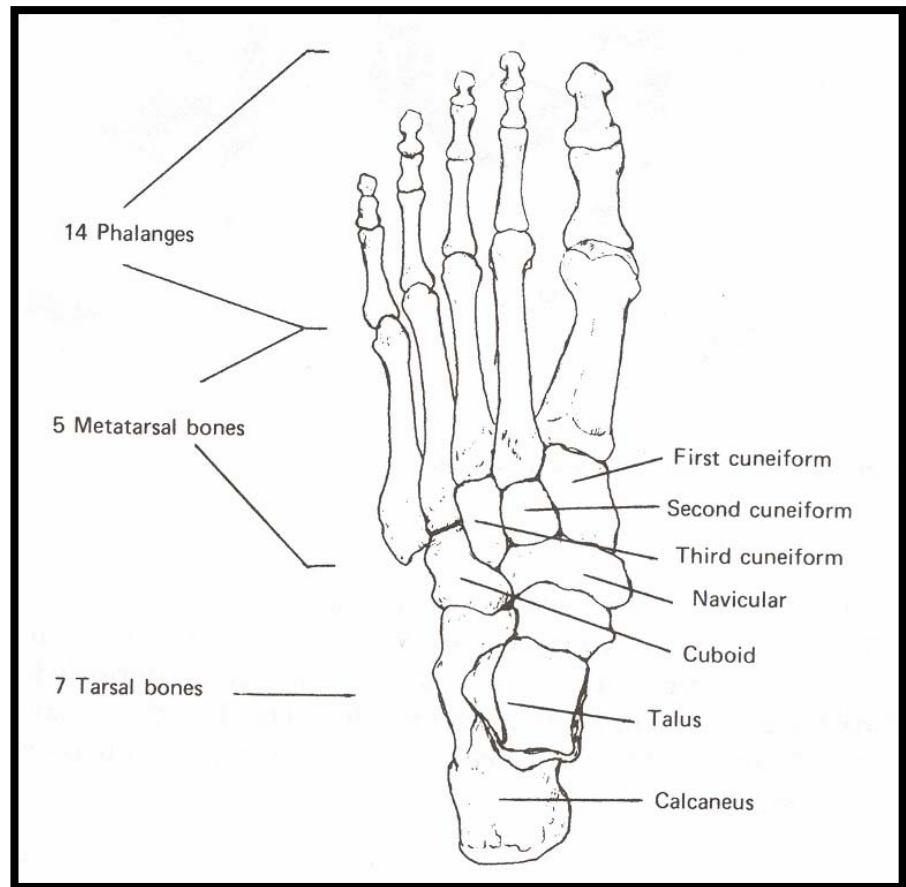
- Trochlea
- Head
- Siding
 - lateral malleolar facet is more projecting than medial
 - head angles medially



Metatarsals (5)

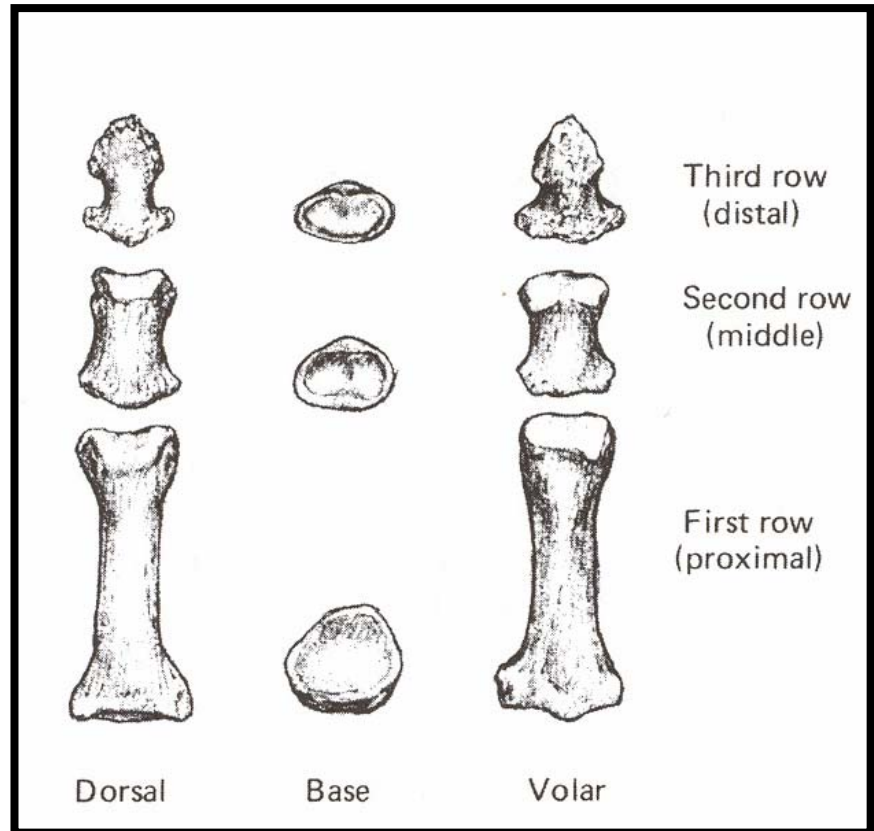


- Labeled M1 - M5
 - Labeled from medial to lateral
- First is by far largest
- Fifth has basal tuberosity
- Convex distal facets with keel
- Concave proximal facets



Phalanges (14)

- Three rows as in hand
- **Hallux** only has two (like pollex)
- Hallucal phalanges much more robust than others



Foot Bone Growth

- Tarsal Bones:
 - Single Ossification Center (several variably have two), except calcaneus: tuberosity has an epiphysis appears in 6-8th year
 - Calcaneus first (3rd prenatal month), navicular and intermediate cuneiform last (3rd year)
 - Calcaneal epiphysis unites 14-16th year
- Metatarsal Bones II-V:
 - Proximal and Shaft: 9-10th week
 - Distal End: 2nd year
 - Unite between 15-19th year
 - MT I is like a phalanx, shaft: 9th week, proximal end 2-3rd year, uniting ~15-17th year
- Phalanges:
 - Proximal End: ~8-11th week
 - Shaft and Distal: 2-4th year
 - Unite 14-18th year

Manual and Pedal

- Carpals are smaller than tarsals
 - Identify all in articulated specimen
 - Talus and Calcaneus in isolation
- Metacarpals vs. metatarsals:
 - Proximal MTs are mediolaterally compressed
 - MT shaft is deeper and straighter
- Manual vs. pedal phalanges
 - Manual longer than pedal
 - Pedal have more “waisted” or constricted shaft
 - Manual have a “D-shaped” cross-section, pedal are circular

Sesamoid Bones

- Hand – usually palmar M1 and M2
- Foot – many possible